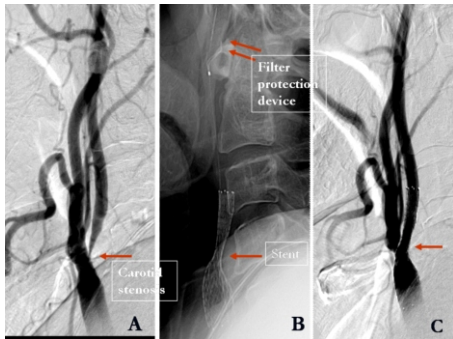


Case Study

Carotid and Vertebral Artery Stenosis

Stenting for Severe Carotid Stenosis

A 64-year old male presented with recurrent numbness of left side of body (transient ischaemic attacks)



- A- Right ICA angiogram revealing severe stenosis of ICA at its origin (arrow)
- B- Stenting procedure shows the stent (single arrow) across the stenosis along with the protection filter device (double arrow) in the distal ICA.
- C- Angiogram after stenting reveals good opening of right ICA stenosis (arrow).