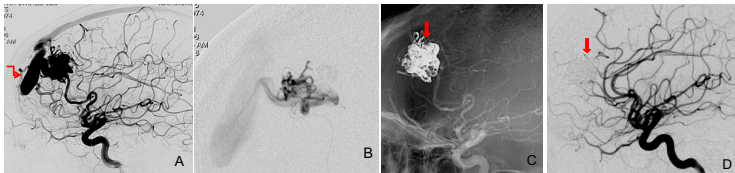


Case Study

Arteriovenous Malformations

Curative AVM Embolization with ONYX

A 24-year-old male presented with seizures. MRI showed a AVM. DSA revealed an AVM in frontal region along with a large venous aneurysm. Since the aneurysm presented a weak spot in the AVM, embolization was performed. After placing the microcatheter in the nidus, the aneurysm was embolized with ONYX. F/U angiogram revealed complete occlusion of the AVM.



A- Angiogram showing an AVM

B- Microcatheter in nidus

C- ONYX cast

D- Angiogram showing complete obliteration of the AVM