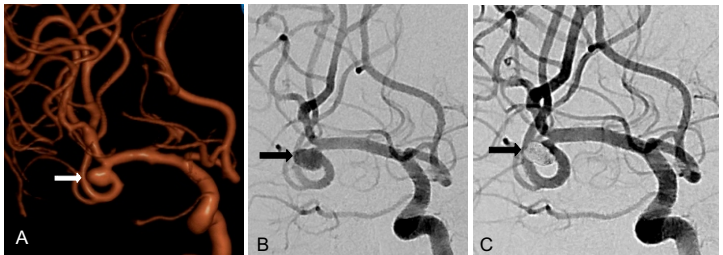


## Case Study

### Cerebral Aneurysm

#### Embolization of Broad Neck Middle Cerebral Artery (MCA) Aneurysm

A 53-year-old female presented with subarachnoid hemorrhage due to a ruptured right MCA aneurysm with a very broad neck. Coiling was done in the same sitting using 3D coils with complete occlusion of the aneurysm.



- A- 3D Angiogram shows broad neck middle cerebral artery aneurysm
- B- Angiogram showing the aneurysm
- C- Post coiling angiogram shows complete occlusion of the aneurysm