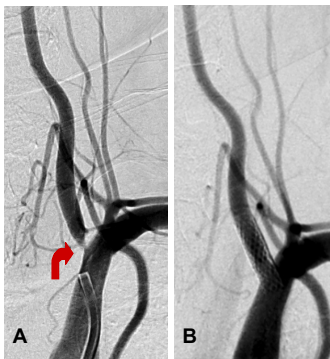


## Case Study

### Carotid and Vertebral Artery Stenosis

#### Vertebral Artery Stenting

A 38-year old male presented with posterior circulation stroke. He made almost complete recovery. Angiogram revealed complete occlusion of right vertebral artery and 90% Ustenosis of left vertebral artery. Under local anesthesia a balloon mounted stent was placed with complete recanalization. Patient made uneventful recovery.



A- DSA shows marked narrowing of vertebral artery origin  
B- DSA shows complete recanalization after stenting