

# CCSVI *Study*

Liberation Treatment - 158 patients

- Dr Vipul Gupta
- Dr Sumit Singh
- Dr Tariq Matin

**CCSVI Unit**  
*Institute of Neurosciences*



## TEAM



### Dr Vipul Gupta

*Head - Neurovascular Interventional Unit*

Dr Vipul trained in Interventional Neuroradiology in All India Institute of Medical Sciences and worked as Associate Professor in AIIMS. He was previously Head Interventional Neuroradiology at Max Super Speciality Hospital (New Delhi). Fellow of Foundation Rothschild, Paris; Cleveland clinic (USA) and in Italy; He is among the first in our country to use dedicated intra cranial stents and 3D-DSA for aneurysm embolization, and has been visiting Professor in UMASS General Hospital, Boston, USA. He specializes Intracranial aneurysms embolization (coiling), AVM embolization, angioplasty and stenting of arterial stenosis including carotid stenting, Intraarterial Thrombolysis for stroke and Percutaneous spinal procedures such as vertebroplasty and other interventional procedures.

Mobile : **+91 9810542372**, E-mail : **vipul.gupta@medanta.org**



### Dr Sumit Singh

*Head - Multiple sclerosis Services*

A topper in DM neurology from All India Institute of Medical Sciences (AIIMS), New Delhi, he was Associate Professor of Neurology at AIIMS. He is known for his contribution in the field of Movement disorders, headache and Neuromuscular disorders. He specialized in Botulinum injections in spasticity, Limb dystonias and facial and limb dyskinesias, spasmodic dysphonias and writer's cramp. He initiated the use of botulinum toxin in Headache for the first time in the country, and extended its usage in trigeminal Neuralgia. Dr Sumit has been with Deep Brain Stimulation Program for Parkinson's disease at AIIMS and was involved in intraoperative assessment and post operative programming of these patients. He has innovated the plasma exchange protocols for diseases such as AIDP, Myasthenic crisis. He also started the first headache clinic in north india.

Mobile : **+91 9810052615**, E-mail : **sumit.singh@medanta.org**



### Dr. Tariq Matin

*Neurovascular Interventional & Doppler expert*

Mobile : **+91 9891047587**

E-mail : **tariq.matin@medanta.org**



### Dr Kalyani Karkare

*Associate Consultant - Neurology*

Contact No. **+91 9910309373**

E-mail - **kalyani.karkare@medanta.org**

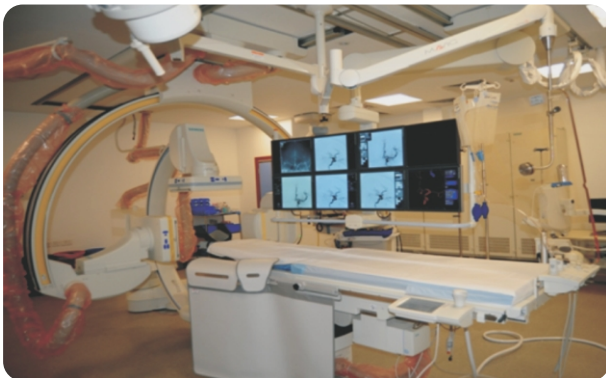## MEDANTA CCSVI EVALUATION PROTOCOL

- Clinical evaluation by Neurologist
- MRI brain, spine with contrast
- MR venography brain neck and upper chest
- Neck Doppler by CCSVI protocol with intracranial doppler study
- Physiotherapy evaluation
- Neuro-psychology evaluation

## LIBERATION (VENOPLASTY) PROCEDURE

- Procedure is performed in local anesthesia along with sedation. Venography is performed through one of the leg veins followed by balloon angioplasty of stenosis
- Post - Venoplasty re - evaluation - doppler, neurology and physiotherapy for response of the procedure
- Follow - up through e-mail questionnaire

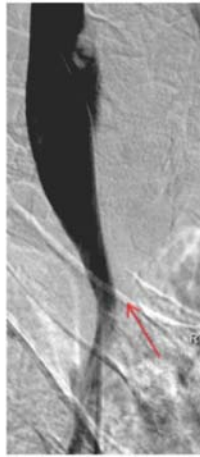
## TECHNOLOGY



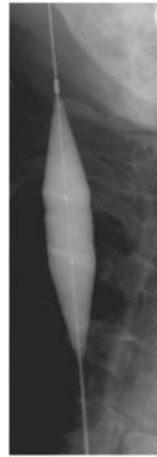**STATE OF ART BIPLANE NEUROENDOVASCULAR LAB  
with 3D and inbuilt CT**

## PATIENT DATA

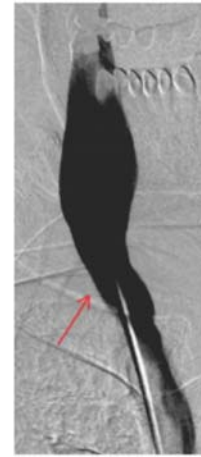
- No of patient = 158
- 58 Male and 100 female
- Type of MS
  - ⇨ PPMS 57
  - ⇨ RRMS 41
  - ⇨ SPMS 60



RT IJV lower end stenosis

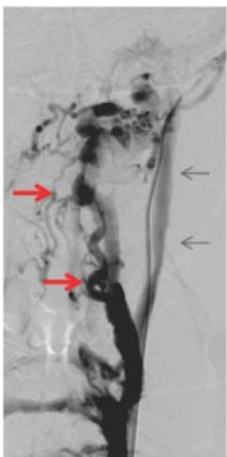


Balloon angioplasty

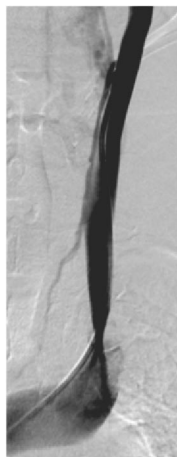


Post angioplasty RT IJV lower end shows significant opening up.

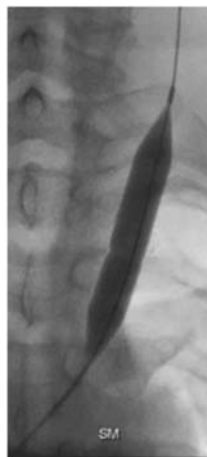## BALLOON ANGIOPLASTY OF RIGHT LOWER END INTERNAL JUGULAR VEIN



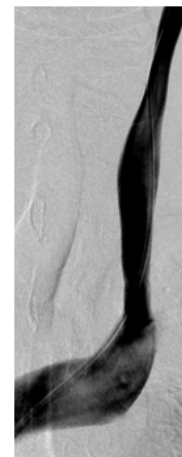Slow flow seen in left IJV (arrow) - Most of flow is by collaterals (red arrowhead)



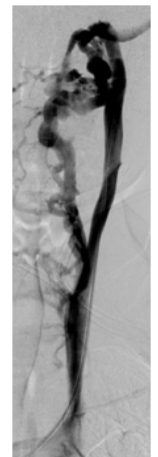
Lower end stenosis of left IJV



Balloon angioplasty

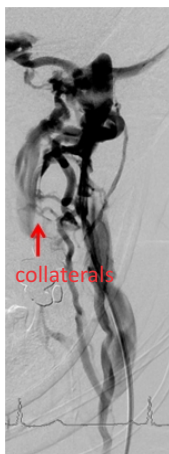

Post angioplasty opening of left lower end IJV stenosis



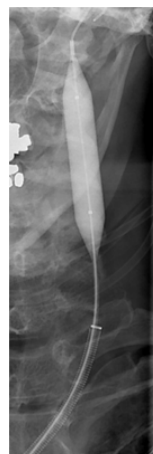Reduction in collateral flow

## BALLOON ANGIOPLASTY OF LEFT LOWER END INTERNAL JUGULAR VEIN

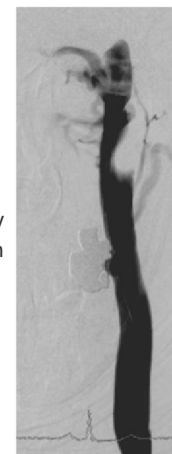


Stenosis left upper end with almost no flow in IJV

collaterals

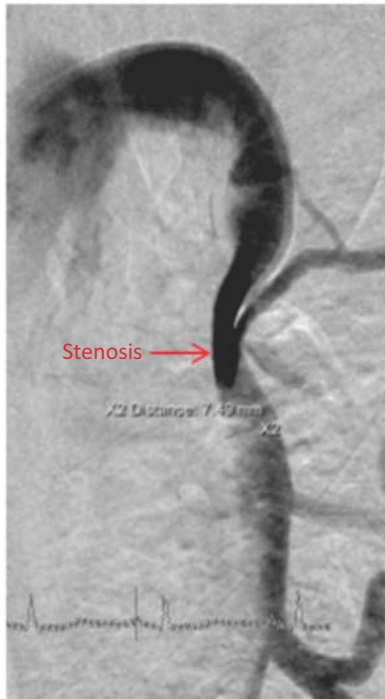

Balloon angioplasty

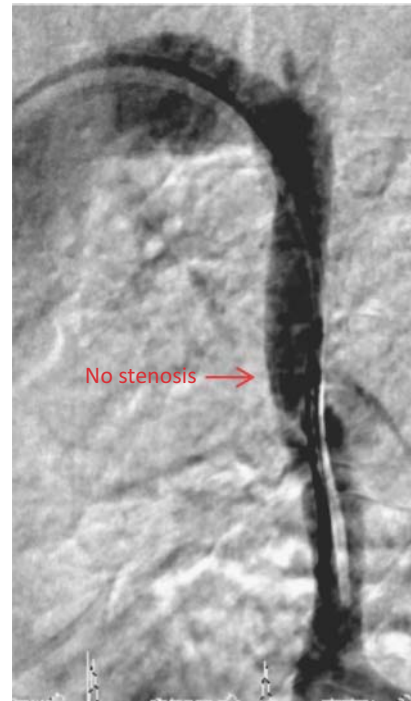


Post angioplasty good flow in vein

## BALLOON ANGIOPLASTY OF LEFT UPPER END INTERNAL JUGULAR VEIN



Azygous vein venography Showing stenosis



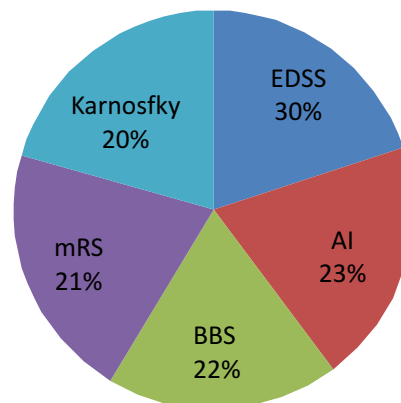
Post balloon angioplasty

## AZYGOUS VEIN ANGIOPLASTY

### Post procedure improvement in our patient

- 60% show subjective improvement
- 40% show objective improvement
- More improvement last 50 cases - learning curve
- Commonly improvements are seen as
  - Better balance - and walking
  - Strength in lower limbs
  - Feeling of warmth
  - Disappearance of mental fogging
  - Swallowing
  - Bladder incontinence
  - Vision
  - INO

### MS IMPROVEMENT SCALES



### Impressions...

1. There is association between extra cranial venous drainage abnormality and Multiple Sclerosis.
2. Exact relationship may be more complex
3. The Liberation procedure does improve symptoms in many patients and some of the improvements may come slowly.
4. However, we cannot be certain about long-term results at this stage.

### On-going CCSVI studies at Medanta - The Medicity

- Relationship between intracranial venous anatomy and the extra-cranial stenosis.
- Long-term follow-up of patients after Liberation procedure
- Detailed evaluation of angiographic in MS patients

**Please Note :** CCSVI Liberation treatment is an on going study and its results and long term outcomes are awaited.....